

Information Snapshot – Mr Jose Cid Fernandez

Clinical Update on Nipple Discharge

Most nipple discharge is benign in nature and does not require surgical intervention. Up to 10% of cases harbour an underlying in situ or invasive malignancy. Assessment is aimed at differentiating these causes.

Causes

Nipple discharge elicited by squeezing of the nipple or from pressure on the breast (e.g. post mammogram) is physiological and not of concern, as is milk production during pregnancy and for several months after cessation of breast feeding.

Galactorrhoea is pale milky discharge arising from multiple ducts, spontaneous, bilateral, often copious, and unrelated to pregnancy or occurring long after discontinuation of breast feeding. It can be caused by abnormally high prolactin levels secondary to a pituitary tumour, or by hypothyroidism. Hyperprolactinemia (>1000 mIU/L) can also be caused by some drugs (e.g. oral contraceptives, HRT, antidepressants, opiates, and antihypertensives).

Thick yellow/brown discharge from multiple ducts, unilateral or bilateral, can result from duct ectasia, a benign dilatation of the terminal milk ducts that is more prevalent in postmenopausal women.

Blood stained single duct discharge is more likely to be associated with intraductal papillomas, epithelial hyperplasia, or less commonly DCIS or invasive carcinoma. The association with an underlying malignancy is higher in older patients.

Assessment

The important features to ascertain from the clinical history are whether the discharge arises from one duct or many, is induced or spontaneous, is coloured or blood stained, and whether it affects one or both breasts. The frequency and consistency of the discharge is also noted. Breast examination may indicate the presence or absence of a breast mass, or an abnormality affecting the skin of the nipple and areola.

Investigation

Mammography, breast ultrasound, and discharge cytology are the main tools employed to investigate single duct discharge. Mammography is particularly useful in women over the age of 35. It specifically looks for microcalcifications suggestive of DCIS. Ultrasound can identify papillomas and cancers in ducts close to the nipple. Cytology of the discharge fluid has poor sensitivity to detect malignancy. However, in the absence of clinical concerns or imaging abnormalities, a smear showing normal epithelial cells with no atypia can be reassuring. Ductal lavage can increase the yield of simple cytology, but its use has not been widely accepted.

Hemocult testing to determine the presence of blood in the discharge fluid is of little value due to its poor sensitivity.

Ductography and ductoscopy, where available, can be useful adjuncts to localise intraductal lesions before surgery.

Prolactin and TSH levels are checked if discharge is bilateral, multi-duct and white.

Altered colour changes, and eczematous changes, of the nipple and areola are investigated with full thickness biopsy under local anaesthesia to exclude Paget's disease.

Management

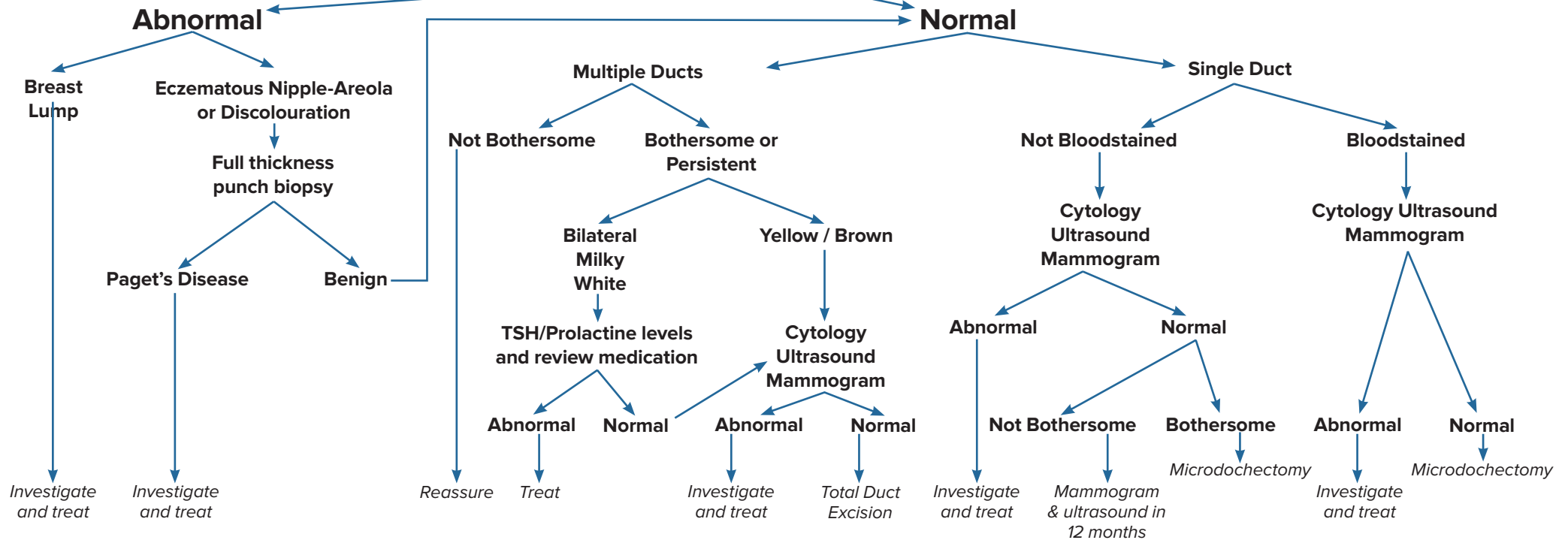
When discharge is associated with a significant abnormality, such as a breast lump on examination, calcified DCIS on mammography, or Paget's disease of the nipple on punch biopsy, comprehensive assessment of this usually requires further imaging and/or pathology tailored to the underlying condition, prior to definitive surgical treatment.

If no significant abnormality is found on clinical examination or imaging the patient is managed according to whether the discharge is from a single duct or from multiple ducts as follows:

- Multi-duct discharge without worrying features, and transient or not affecting quality of life, does not require treatment. Reassurance is often enough, and, for those who have discharge on breast expression, advice to refrain from squeezing their nipples and breasts is also important. For women with persistent and/or bothersome discharge this can be treated surgically by total duct excision. The operation is carried out through a circumareolar skin incision and involves dividing the milk ducts from the underside of the nipple.
- Single duct discharge which is not blood stained and is transient or intermittent can be reassessed with repeat mammogram and ultrasound at 12 months. Surgery is indicated if the discharge is either blood stained, or persistent (i.e. > twice per week) or associated with an underlying papilloma or with atypical cells on cytology. A single milk duct can be removed by microdochectomy. This requires identification and cannulation of the offending duct with a small probe prior to dissecting it out from surrounding breast tissue. Total duct excision is less likely to miss an underlying malignancy, and thus a good alternative for women not concerned with the ability to preserve breast feeding.

Nipple Discharge

Breast Examination



About Mr Jose Cid Fernandez

Mr Cid Fernandez is an Oncoplastic Breast Surgeon and General Surgeon who has worked in public hospitals in Perth since 2008. He has recently joined the multidisciplinary breast cancer care team at the Perth Breast Cancer Institute in Hollywood Hospital, and he offers consultation services for all aspects of benign and malignant breast conditions and reconstructive breast surgery. Mr Cid Fernandez can see patients within a few days and is available for urgent consultations as required. He holds a public appointment as a Consultant Breast Surgeon at Fiona Stanley Hospital. For more information on Mr Cid Fernandez please click [here](#)

For Enquiries & Appointments
Perth Breast Cancer Institute
 Hollywood Consulting Centre
 Suite 405, 91 Monash Avenue
 Nedlands WA 6009

T (08) 6500 5570
 F (08) 6500 5577
 E reception@drjose.com.au
 W www.drjose.com.au
 Healthlink: drjosecf

Hollywood Private Hospital
 Monash Avenue, NEDLANDS WA 6009
T (08) 9346 6000